

## Focal Compressive Indentation Injury Comparison Between Post-mortem Human Subjects and Ventral Porcine Tissue

Kyle L. Ondar, Eugene Ablordeppey, Philip J. Brown, Joel D. Stitzel, F. Scott Gayzik

### I. INTRODUCTION

In the United States, there are 12 million non-fatal injuries annually in homes and surrounding areas [1]. Cutting or piercing injuries account for 11.3% of these incidents, resulting in minor trauma [1]. Without proper treatment, there is an increased risk of complications such as infections or scarring [2]. It is uncertain if the skin's response to these injuries varies by body region.

The purpose of this study is to quantify the gross injury mechanisms of dermal and epidermal layers of the skin under focal compressive loading. Safety standards from NASA and ECE-R require a minimum safety radius of 2.0 mm or greater [3-4]. Previous studies compared a sharp knife-edge blade (8.5  $\mu\text{m}$ ) to a blunted impactor of 0.2 mm [5]. This study focused on ventral porcine skin, which is a well-documented surrogate for human tissue [6], specifically in terms of tensile loading. The relationship of ventral porcine skin to post-mortem human subject (PMHS) skin under focal compressive loading is currently unknown and is the primary objective of this study. Further, a secondary investigation using this data will investigate how the radius of the impactor profile affects injury over a relevant range of blunt impactor radii. Finally, a comparison of five extraction locations was conducted to determine if specific PMHS locations develop injuries differently.

### II. METHODS

The porcine skin acquired for this study was sourced from a congruent study being performed at the Wake Forest School of Medicine Pediatric Surgery Department (IACUC A21-173 & A22-047). All 44 porcine samples were sourced from  $n=10$ , 8- to 10-month-old Yorkshire crossbred pigs. All samples were collected within two hours of animal sacrifice. Directly after sacrifice, two bilateral rectangular sheets measuring approximately 150 mm by 100 mm were removed from the ventral region of the abdomen of the animals, the whole region excised was treated as uniform. A #23 scalpel was used to remove all adipose tissue on the dermal side of the samples such that just the dermis and the epidermis were remaining. A clicker press was used to punch sample coupons measuring 100 x 10 mm. Prior to testing, specimens were kept wrapped in room temperature, saline-soaked gauze. All testing occurred within 12 hours of sacrifice.

Four PMHS donors, three females and one male, were used to collect the remaining tissue required. Five regions were selected as extraction points: forehead (FH  $n=13$ ), anterior forearm (AF  $n=13$ ), posterior forearm (PF  $n=7$ ), upper arm: predominantly triceps (UA  $n=17$ ), and sub-mammary chest (SM  $n=13$ ). In total, 63 PMHS samples were successfully extracted and prepared in the manner discussed previously. Each rectangular specimen was tested in a custom-built tension jig (Fig. 1) held in place with 35 psi pneumatic clamps. The specimen was laid flush on a Delrin stage, and measurements of its length, width, and thickness were recorded in situ, and 20 N of tension was applied to simulate physiological state of skin [3]. We compared the in-situ skin length and width data prior to cutting to the tensioned specimen and on average, there was only a 10% change. Once the specimen reached the expected 20 N of tension, each specimen was subjected to one of five indenters (0.5 mm, 0.75 mm, 1.0 mm, 1.5 mm, 2.0 mm) and compressed to 95% of the thickness of the sample's original tensioned




Fig. 1. Experimental setup affixed to a material test frame. 1.0 mm radius end effector pictured.

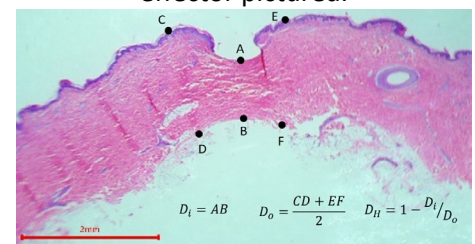


Fig. 2. Porcine histology after 1.5 mm indenter compressed to 95% of its thickness.

thickness at 100 mm/s. Tensile and compressive forces were collected from load cells in the transverse and axial planes respectively. Post-test, each sample was fixed in a formalin solution and stained with a Hematoxylin & Eosin stain (H&E) to assess injury to the dermis. Eight histology slides per sample were analyzed to assist in quantifying the injury classifications. A ratio of compressed skin thickness focally under the indenter to surrounding undamaged thickness was measured bilaterally from the location of applied loading, this metric is histological depth,  $D_H$  (Fig.2). With this approach, 0.0 was considered no injury and 1.0 was considered full bisection in which there is no connection between the two dermal pieces around the focal compression point. Figure 2 demonstrates an injury of 0.45 histological depth. This was done on a per slide basis, and the average damage over the eight slides with standard deviation was recorded. Slides that were not readable were discarded, reducing the number of measures that contributed to the average. All statistical analysis was performed using JMP software v 13 (SAS, Cary, North Carolina). A one-way analysis of variances tests (ANOVA) with a Tukey post hoc test and an unpaired t-test, when appropriate, were used to identify statistical differences between the species and location sets of data ( $\alpha = 0.05$ ).

### III. INITIAL FINDINGS

Maximum force normalized by the width of specimen and the radius of indenter (e.g. stress or pressure) is presented (NMaxForce). Histological depth, defined as the ratio of the depth of tissue damage to undamaged thickness, was used to quantify injury. Stratifying normalized force data by species and radius, there was no significant difference found between interspecies radii ( $p > 0.11$ ) (Fig. 4). Investigating radii by species, there is significance between the normalized force porcine radii experienced as they increased from 0.5 mm to 2 mm ( $p < 0.0007$ ) (Fig. 4), while no statistical difference in any group was found for PMHS ( $p > 0.08$ ) or either species in histological depth ( $p > 0.06$ ) (Fig. 6). By location, the porcine data are similar to upper arm and posterior forearm ( $p > 0.06$ ) while sub-mammary is different from all other measures ( $p < 0.001$ ) (Fig. 3). Stratifying by radius and species, there is significant difference in histological depth for 0.75 mm, 1 mm and 2mm paired radii between species ( $p < 0.01$ ) (Fig. 6). Finally, histological depth showed no significant difference in regional PMHS data ( $p > 0.4793$ ) while the ventral porcine demonstrated no significant difference from forehead or posterior forearm data ( $p > 0.4704$ ) (Fig. 5).

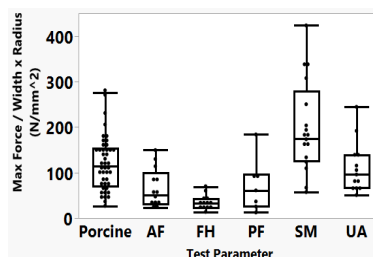


Fig. 3. B&W comparing NMaxForce regionally

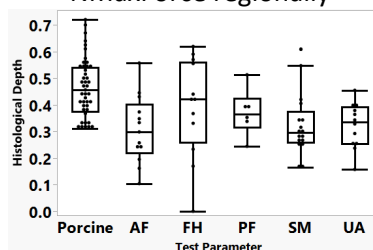


Fig. 5. B&W comparing histological depth regionally

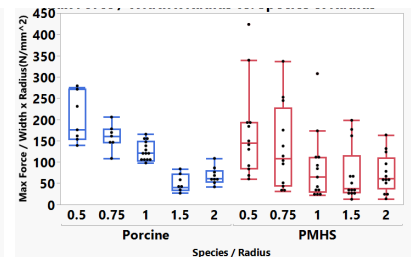


Fig. 4. B&W comparing NMaxForce stratified by radius and species.

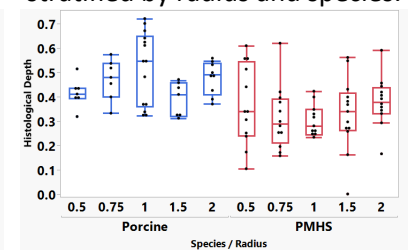


Fig. 6. B&W comparing histological depth stratified by radius and species.

### IV. DISCUSSION

This study had three objectives. First, to investigate the injury response relationship between PMHS and porcine skin samples under focal compressive loading. Second, to investigate the relationship between indenter radius and injury expression. Finally, to quantify regional differences in PMHS skin injury expression. On average, ventral porcine skin is as stiff as or stiffer than most tested PMHS regions (Fig. 3). As a surrogate, its ability to express injuries that are clinically similar in depth may be relevant. While stratification was seen between the regions of normalized force (Fig. 3), this trend was not as pronounced in histological depth (Fig. 5). Regardless of radii, we saw no intra-species difference in the histological depth (Fig. 6). Smaller radii developed significantly more pressure on the skin and yet resulted in little difference in observed histological depth. This may imply the injury is a strain-based event and not a stress-based event. While this study held a constant compression of 95% tissue depth, a future study could evaluate the onset of injury by varying compressive depth, or compressive rate. Finally, we saw no differences in most PMHS regions tested. This implies a homogenous response can be expected from skin taken from the head and arms, regardless of donor, relative to the regions tested.

**V. REFERENCES**

[1] Gielen, A., *et al.*, *Ann Rev Pub Health*, 2015.  
[4] NASA, STD-3001, Vol.2, 2019.

[2] Kretlow, J., *et al.*, *Semin Plast Surg*, 2010.  
[5] ECE-R, ICEPS, 2000.

[3] Ito, M., *J Mech in Med and Bio*, 2017.  
[6] Gallagher, A., *et al.*, IRCOBI, 2012.