Assessment of a Perfusion and Ventilation Method for Detecting Soft Tissue Injury in a Post-Mortem Human Subject Model through Histological Examination

Cynthia A. Bir, Karin A. Rafaels, Monica Wong, Meghan Lewis, Kenji Inaba

I. INTRODUCTION

The use of post-mortem human subjects (PMHSs) has been well documented for advancement of injury biomechanics research. One of the limitations of using PMHSs for the assessment of injuries related to an impact event is the lack of active processes such as blood circulation and ventilation. Although perfusion techniques have previously been employed, they have primarily provided a means to create a static pressurised environment for more representative loading, not necessarily for detailed evaluations of organ injury. Improper techniques can lead to unintentional damage, fluid loss, incomplete perfusion, or inadequate stresses [1-12].

A PMHS perfusion model was recently developed for surgical simulation training to represent a living human [13-16]. This model has been successfully implemented in the past for the simulation of minimally invasive spinal surgery [17], plastic surgery [18], cranial surgery [19], cardiothoracic surgery [20] and even for extremity tourniquet evaluation [21]. Because this model can demonstrate bleeding of incised skin tissue and the ability to simulate injuries [14], the objective of this study was to assess the applicability of the surgical simulation model to an injury biomechanics application where evaluating contusions within soft tissue in the absence of skeletal injury is important, i.e., behind-armour blunt trauma (BABT).

II. METHODS

Three case studies of BABT incidents resulting in contusions to internal organs were identified from a previously-established database of real-world incidents of law enforcement officers who have survived a non-perforating, ballistic impact to their body armor [22]. For each of the selected cases, an exemplar piece of body armour and the stated threat level were used to recreate the incident on the PMHS perfusion model in the Biomechanics Injury Research Laboratory at the University of Southern California (USC), USA.

All of the three fresh, never frozen, specimens in this study were ethically acquired through Science Care with the assistance of the Anatomical Gift Program (AGP) at USC. The anthropometry of the specimens was selected to match the officer as best as possible. A summary of the cases and test conditions are in Table I.

TABLE I

TEST SUMMARY

	BABT Injury	Officer Anthropometrics	BABT Impact	PMHS Anthropometrics
Case 1	*Anterior lung contusion underlying chest wall contusion*	38-year-old male, 170 cm, 64 kg, BMI 21.9	NIJ II vest made of aramid yarns and fiber, .38 caliber FMJ	80-year-old male, 173 cm, 91 kg, BMI 30.4 (similar torso size to officer)
Case 2	*Posterior lung contusion underlying contusion on right lower back*	32-year-old male, 188 cm, 70 kg, BMI 19.9	NIJ II vest made of aramid yarns and fibers, 9 mm FMJ	76-year-old male, 165 cm, 64 kg, BMI 23.3 (similar BMI to officer)
Case 3	*Liver contusion underlying wound on anterior, right lower torso*	52-year-old male, no height and weight given	NIJ II vest made of aramid yarns and fibers, .357 JHP	77-year old male, 178 cm, 104 kg, BMI 33.0

BMI – Body Mass Index, NIJ – National Institute of Justice, FMJ – Full Metal Jacket, JHP – Jacketed Hollow Point

To pressurise the vasculature, the femoral artery and vein were cannulised and connected to tubing leading to two recirculation pumps: one for the arterial system and another the venous system. The blood within the specimen was removed from the body by pressurising the vascular system for 20 second intervals and performing compression, as needed. A shear-thinning blood surrogate consisting water, saline and premium-grade tempera paint (1.75% salinity) was pumped through the arterial and venous systems, taking care to ensure that no air was present within the fluid lines. A Swan-Ganz catheter was placed via the jugular vein to measure the central venous pressure, with a goal of maintaining 8-10 mmHg. The specimens were also

C. Bir (cbir@wayne.edu, +1-315-577-7821) is the Chair of Biomedical Engineering at Wayne State University, Detroit, MI, USA. K. Rafaels is a Biomedical Engineer at the US DEVCOM Army Research Laboratory in Aberdeen Proving Ground, MD, USA. Monica Wong, Meghan Lewis, and Kenji Inaba are all at the Keck School of Medicine, USC, Los Angeles, CA, USA.

intubated and ventilated at a rate of 12-16 breaths per minute with a tidal volume of 450 mL, and a two-second inspiratory time. A positive end-expiratory pressure of 5-12 cmH_2O was used to keep the alveoli from collapsing.

A harness was used to suspend the specimen wearing the exemplar armour (Fig. 1). The shot location and muzzle-to-armour distance were determined from the case data. Prior to the impact, the ventilation and perfusion were initiated and confirmed to be at the desired physiologic levels. As soon as the impact event was over, the perfusion and ventilation were suspended. After a post-impact autopsy was conducted by a board-certified trauma surgeon to identify internal injuries, small tissue samples were taken to conduct histological analysis using the hematoxylin and eosin (H&E) stain.



Fig 1. Test setup after perfusion and ventilation were established.

III. INITIAL FINDINGS

Histological samples were taken from the impacted and the non-injured areas (to act as a control for each specimen). The impacted area often demonstrated a discoloration, potentially indicating a *bruise*. For Case 1, the samples revealed more *blood* within the smooth muscles and connective tissue of the bronchioles compared to the non-impacted region (Fig. 2). For Case 2, there appeared to be more debris and *blood* in the alveolar spaces in the impacted sample than in the control (Fig. 3). For Case 3, more *blood* was present in the parenchyma from the impact section compared to the non-impacted areas (Fig. 4).

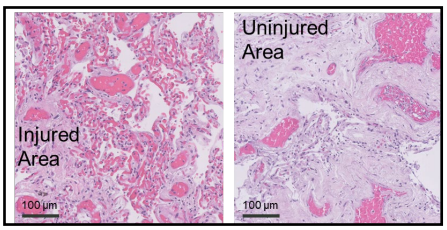

Fig 2. H&E-stained lung demonstrating extravasated "blood" in the impacted area compared to the non-impacted.

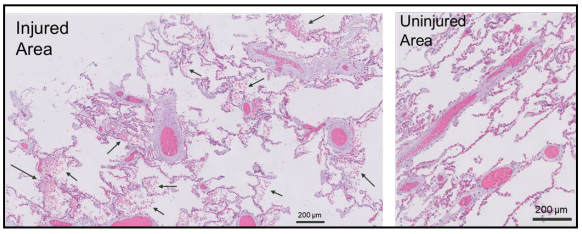

Fig 3. H&E-stained lung demonstrating diffuse alveolar damage in the impacted area compared to the non-impacted area.

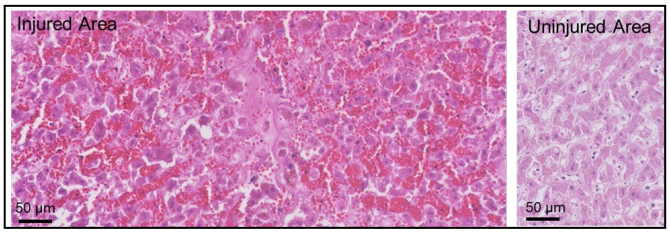

Fig 4. H&E-stained liver demonstrating extravasated "blood" in the impacted area compared to the non-impacted area.

IV. DISCUSSION

Based on the results of the current effort, the feasibility of using the perfusion/ventilation model for soft tissue injury assessment in a PMHS model seems promising. The methods to pressurise and ventilate the specimens provided realistic conditions within the PMHS without damaging the tissue. The histological analysis demonstrated perfusion of the vasculature to the small vessels, no areas of ventilator-induced lung damage, and non-collapsed alveoli. Furthermore, for all three case studies, the presence of internal organ injuries documented in the cases was confirmed in the histological analysis. The histology analysis indicates that organ contusion injuries could potentially be assessed using this perfusion method. Additional work is taking place to further validate this PMHS perfusion model.

V. ACKNOWLEDGEMENTS

The authors thank Mike Minneti for sharing his expertise of the PMHS perfusion model. The authors also thank Rodrigo Villalta, Donald Sherman, and Erika Matheis for their contributions to this project.

VI. REFERENCES

[1] Kroell CK et al, Stapp, 1971. [2] Smith RW, Int Wkshp Human Subjects Biomech Res, 1977. [3] Kallieris D et al, Int Wkshp Human Subjects Biomech Res, 1994. [4] Viano DC et al, Accid Anal Prev, 1989. [5] Long MT, Dissertation, 2009. [6] Tarriere C, Int Wkshp Human Subjects Biomech Res, 1974. [7] Cromack JR, Int Wkshp Human Subjects Biomech Res, 1974. [8] Slutsky AS et al, NEJM, 2013. [9] Mead J et al, J Appl Physiol, 1970. [10] Kent RW et al, Obesity, 2010. [11] Salzar RS et al, IRCOBI, 2008. [12] Malhotra A, NEJM, 2007. [13] Bakhsheshian JB et al, Spine, 2017. [14] Carey JN et al, Am J Surg, 2015. [15] Minneti M et al, J Surg Educ, 2018. [16] Minneti M et al, J Trauma Acute Care Surg, 2019. [17] Buchanan IA et al, Oper Neurosurg, 2019. [18] Carey JN et al, J Plast Reconstr Aesthet Surg, 2014. [19] Christian EA et al, J Neurosurg, 2018. [20] Greene CL et al, Ann Thorac Surg, 2015. [21] Cremonini C et al, J Trauma Acute Care Surg, 2021. [22] Bir CA et al, International Symposium on Ballistics, 2017.